

## Grave's Ophthalmopathy in the Absence of Abnormal Thyroid Hormone and Thyrotropin Levels and Thyrotropin Receptor Antibody

Hidekatsu Yanai<sup>1</sup> and Hiroko Yamazaki<sup>2</sup>

<sup>1</sup>Department of Internal Medicine,  
National Center for Global Health and Medicine,  
Kohnodai Hospital, Ichikawa, Chiba 272-8516, Japan.

<sup>2</sup>Department of Ophthalmology,  
National Center for Global Health and Medicine,  
Kohnodai Hospital, Ichikawa, Chiba 272-8516, Japan.

*Corresponding author:* Hidekatsu Yanai, M.D., Ph.D., F.A.C.P.,  
The Head, Department of Internal Medicine, National Center for Global Health and Medicine,  
Kohnodai Hospital, Ichikawa, Chiba 272-8516, Japan, [dyanai@hospk.ncgm.go.jp](mailto:dyanai@hospk.ncgm.go.jp)

Received: November 19, 2010

Accepted: November 29, 2010

**Abstract.** The onset of Grave's ophthalmopathy is in most cases concomitant with the onset of hyperthyroidism. Grave's ophthalmopathy and Graves' hyperthyroidism are closely associated and thought to be caused by thyrotropin receptor antibodies. Here we will show a patient with Grave's ophthalmopathy demonstrated by magnetic resonance imaging, but who showed normal thyroid hormone and thyrotropin levels and the absence of thyrotropin receptor antibodies. Interestingly, the patient was seen on two occasions 10 years apart with a similar clinical presentation. During the patient's second evaluation, she was found to be positive for thyroid stimulating antibodies; this was the only indication for diagnosing the patient as having Graves' disease.

**Keywords** Grave's ophthalmopathy • Hyperthyroidism • Thyrotropin receptor antibody • Thyroid stimulating antibody

### Introduction

Grave's ophthalmopathy (GO) is one of complications of Graves' disease, which reduces the quality of life of patients with Graves' disease. The onset of GO in most cases concomitant with the onset of hyperthyroidism.

GO has been found to be closely associated with Graves' hyperthyroidism by the same autoimmune process. Thyrotropin receptor antibody (TRAb) is the likely candidate. This is likely because TRAb causes Graves' hyperthyroidism. Also, TRAb appears to be present in the orbital tissues, and the expression of TRAb is augmented in orbital tissues from patients with GO.<sup>[1]</sup> Here we report a patient with GO, who had reference range thyroid hormone and thyrotropin (TSH) levels and was negative for TRAb. Furthermore, the patient was seen on two occasions 10 years apart with a similar clinical presentation.

### Case Report

A 65-year-old woman visited our hospital because of worsening of bilateral eye proptosis and corneal abrasion. At 56 years of age, she also visited our hospital because of proptosis, and her thyroid

function was examined. Serum levels of free triiodothyronine and free thyroxine were 3.3 pg/mL (2.47-to-4.34 pg/mL) and 1.33 ng/dL (0.97-to-1.79 ng/dL), respectively, and her TRAb level was 0% (< 15%). She had not received treatment for Grave's disease and GO.

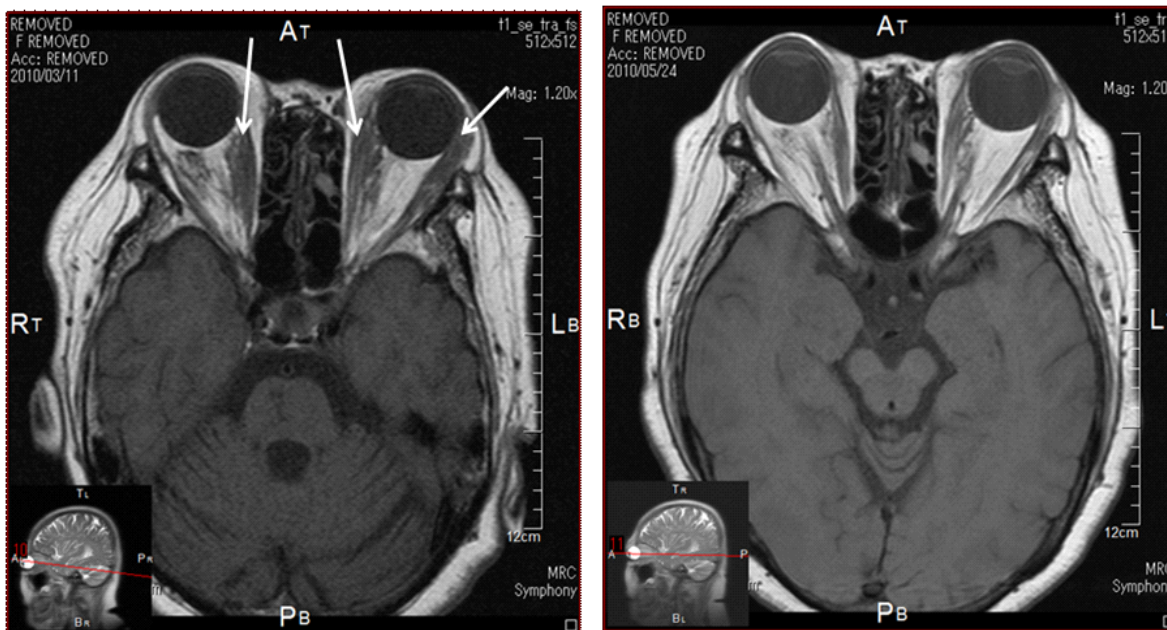
In March 2010, the patient revisited our hospital because of the progression of bilateral proptosis. T1-weighted magnetic resonance imaging (MRI) revealed enlarged eye muscles (Figure 1A), suggesting the existence of GO. She was diagnosed as having GO by an ophthalmologist and referred to our department.

Again, her thyroid function tests results were within their reference ranges: free triiodothyronine (2.96 pg/mL; reference range, 2.39-to-4.06 pg/mL), free thyroxine (1.13 ng/dL; reference range, 0.71-to-1.52 ng/dL), and TSH level (1.35  $\mu$ IU/mL; reference range, 0.54-to-4.26  $\mu$ IU/mL). Her TRAb level was also within its reference range (0%; reference range < 10%). Anti-thyroglobulin antibody and anti-microsomal antibodies were also negative.

During this second patient visit, we measured her thyroid stimulating antibody (TSAb) and found that it was positive (221%; reference range < 180 %). With this test results, she was finally diagnosed as having GO ten years after the onset of her GO. She

## A. Before the corticosteroid treatment

## B. After the corticosteroid treatment



**FIGURE 1.** Magnetic resonance imaging of Graves' ophthalmopathy before (A) and after (B) corticosteroid treatment. Arrows indicate enlarged eye muscles.

was treated with 30 mg of prednisolone orally each day. This corticosteroid treatment ameliorated her GO in 10 weeks (Figure 1B).

## Discussion

The onset of GO in most cases is concomitant with the onset of hyperthyroidism. GO may present before the development of thyrotoxicosis, concomitant with thyrotoxicosis, or after the treatment of thyrotoxicosis. However, our patient had not shown the development of thyrotoxicosis, and also had not yet received treatment for Grave's disease for ten years after the development of GO.

Previously, the prevalence of patients without elevated free thyroxine and free triiodothyronine levels was determined in 1,020 patients with GO.<sup>[2]</sup> The incidence was very rare (19 cases, 1.9%) among patients with GO.<sup>[2]</sup> Among 19 GO patients who did not show elevated serum free thyroxine and free triiodothyronine levels, only 7 patients (0.7%) her reference range TSH levels, and TRAb was detected in all patients.<sup>[2]</sup> However, in addition to having reference range serum free thyroxine, free triiodothyronine, and TSH levels, our patient was absent of TRAb. Tobacco smoking, radioactive iodine treatment, hyper- and/or hypothyroidism, elevated TRAb level, which were considered as risk factors for the development of GO,<sup>[3,4]</sup> were not observed in our

patient.

The only abnormal laboratory finding in our patient was elevated TSAb. Nishikawa M, et al. evaluated the association between eye changes and thyroid-associated autoantibodies. They found that TSAb in Graves' patients with GO was significantly higher than that in patients without GO. They also found that the level of stimulating activity in Graves' patients with GO was significantly positively correlated with the sum of the swelling ratios of the individual eight eye muscles measured using MRI.<sup>[5]</sup> This result is evidence of a significance of TSAb in the development of GO.

## Conclusion

We evaluated a GO patient with normal thyroid hormone and TSH levels and an absence of TRAb. To our knowledge, our observation is the first report to show that untreated GO for ten years was subsequently ameliorated by corticosteroid treatment. The only laboratory basis for diagnosing this patient as having Graves' disease was her positivity for TSAb. Her case warrants the study TSAb levels in other euthyroid, TRAb-negative GO patients.

## References

1. Bahn, R.S. Graves' ophthalmopathy. *N. Engl. J. Med.*, 362:726-738, 2010.

2. Khoo, D.H., Eng, P.H., Ho, S.C., et al. Graves' ophthalmopathy in the absence of elevated free thyroxine and triiodothyronine levels: prevalence, natural history, and thyrotropin receptor antibody levels. *Thyroid*, 10:1093-1100, 2000.
3. Stan, M.N. and Bahn, R.S. Risk factors for development or deterioration of Graves' ophthalmopathy. *Thyroid*, 20:777-783, 2010.
4. Wiersinga, W.M. and Bartalena, L. Epidemiology and prevention of Graves' ophthalmopathy. *Thyroid*, 12:855-860, 2002.
5. Nishikawa, M., Yoshimura, M., Toyoda, N., et al. Correlation of orbital muscle changes evaluated by magnetic resonance imaging and thyroid-stimulating antibody in patients with Graves' ophthalmopathy. *Acta. Endocrinol.*, 129: 213-219, 1993.